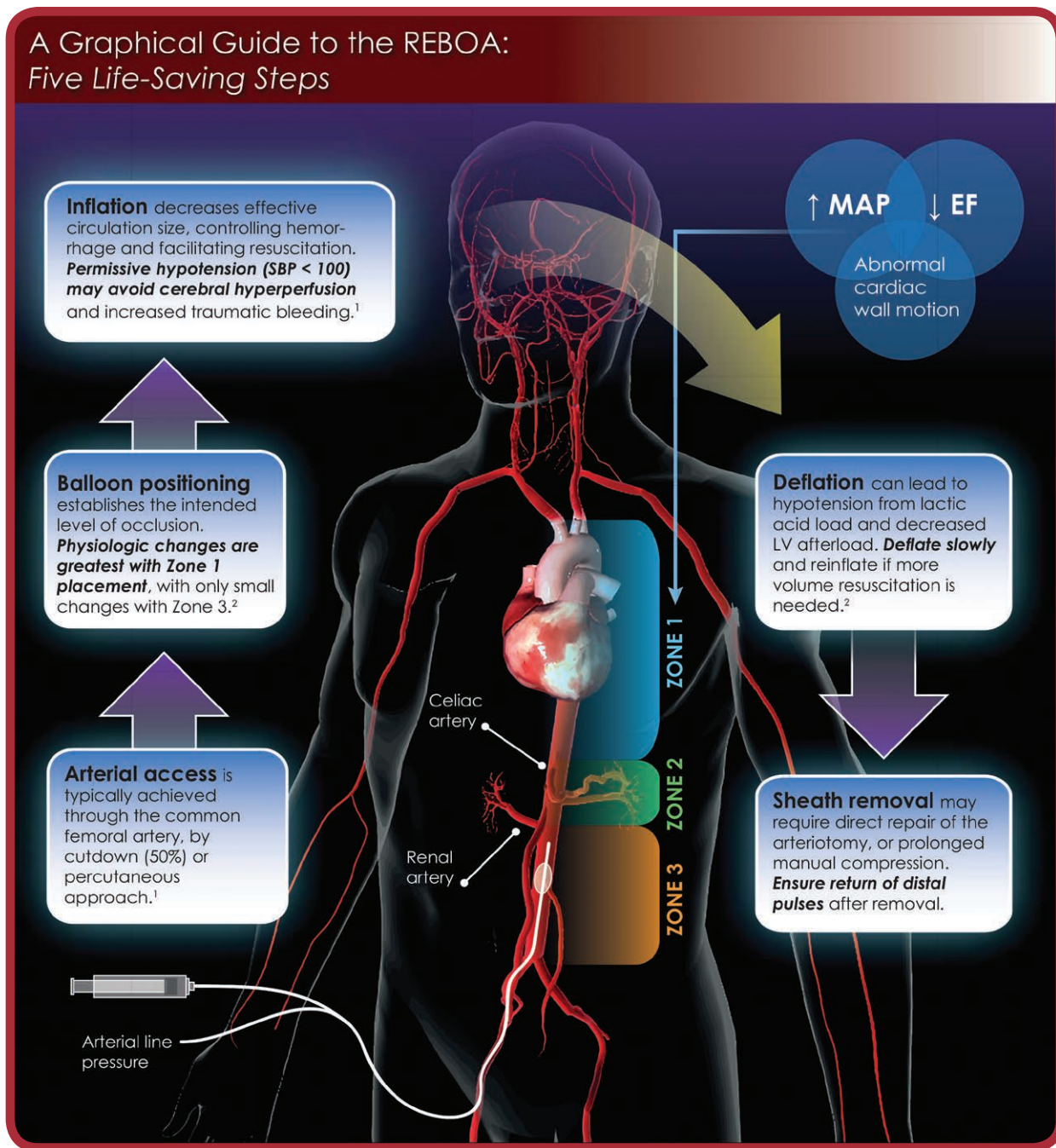


## A Graphical Guide to the REBOA: Five Life-Saving Steps



The introduction of resuscitative endovascular balloon occlusion of the aorta has the potential to dramatically affect the management of noncompressive torso hemorrhage. Early results from clinical application of this new tool have been promising, although high-quality data are still needed to understand the best clinical management strategies. In this infographic, we review the essential steps for resuscitative endovascular balloon occlusion of the aorta usage and the associated considerations for anesthetic management of this patient population.

EF indicates ejection fraction; LV, left ventricle; MAP, mean arterial pressure; SBP, systolic blood pressure.

The Infographic is composed by Jonathan P. Wanderer, MD, MPhil, Vanderbilt University School of Medicine (jon.wanderer@vanderbilt.edu), and Naveen Nathan, MD, Northwestern

Copyright © 2017 International Anesthesia Research Society

**IARS** International Anesthesia Research Society

University Feinberg School of Medicine (n-nathan@northwestern.edu). Illustration by Naveen Nathan, MD.

The authors declare no conflicts of interest.

### REFERENCES

1. Sridhar S, Gumbert SD, Stephens C, Moore LJ, Pivalizza EG. Resuscitative endovascular balloon occlusion of the aorta: principles, initial clinical experience, and considerations for the anesthesiologist. *Anesth Analg*. 2017;125:884–890.
2. Qasim Z, Sikorski R. Physiologic considerations in trauma patients undergoing resuscitative endovascular balloon occlusion of the aorta. *Anesth Analg*. 2017;125:891–894.